


# Simple Adnexal Cysts: SRU Consensus Conference Update on Follow-up and Reporting

Deborah Levine, MD • Maitray D. Patel, MD • Elizabeth J. Sub-Burgmann, MD • Rochelle F. Andreotti, MD • Beryl R. Benacerraf, MD • Carol B. Benson, MD • Wendy R. Brewster, MD, PhD • Beverly G. Coleman, MD • Peter M. Doubilet, MD, PhD • Steven R. Goldstein, MD • Ulrike M. Hamper, MD • Jonathan L. Hecht, MD, PhD • Mindy M. Horrow, MD • Hye-Chun Hur, MD, MPH • Mary L. Marnach, MD • Ed Pavlik, MD, PhD • Lawrence D. Platt, MD • Elizabeth Puscheck, MD • Rebecca Smith-Bindman, MD • Douglas L. Brown, MD

From the Department of Radiology, Beth Israel Deaconess Medical Center, 330 Brookline Ave, Boston, Mass GU, US02215 (D.L.); Department of Radiology, Mayo Clinic Arizona, Phoenix, Ariz (M.D.P.); 1425 S. Main St, Walnut Creek, Calif 94596 (E.J.S.B.); 2115 Sharondale Dr, Nashville, Tenn 37215 (R.F.A.); One Brookline Place, Brookline, Mass 02445 (B.R.B.); Department of Radiology, Brigham and Women's Hospital, Boston, Mass (C.B.B.); UNC Chapel Hill Medical Center, Chapel Hill, NC (W.B.); Children's Hospital of Philadelphia, Philadelphia, Pa (B.G.C.); Department of Radiology, Brigham and Women's Hospital, Boston, Mass (P.M.D.); 530 First Avenue, Suite 10N, New York, NY 10016 (S.R.G.); Department of Radiology, Johns Hopkins University, School of Medicine, Baltimore, Md (U.M.H.); Department of Pathology, Beth Israel Deaconess Medical Center, Boston, Mass (J.L.H.); Einstein Medical Center, Philadelphia, Pa (M.M.H.); Columbia University Medical Center, Department of Obstetrics and Gynecology, Division of Gynecologic Specialty Surgery, New York, NY (H.C.H.); 1848 Century Valley Road NE, Rochester, Minn 55906 (M.L.M.); OB/GYN UKMC, 800 Rose St, Lexington, Ky 40536 (E. Pavlik); 6310 San Vicente, Suite 520, Los Angeles, Calif 90048 (L.D.P.); Wayne State University, C.S. Mott Center for Human Growth and Development, Department of Obstetrics and Gynecology, Detroit, Mich and InVia Fertility, Hoffman Estates, Ill (E. Puscheck); 350 Parnassus Ave, Suite 307C, San Francisco, Calif 94143 (R.S.B.); and Department of Radiology, Mayo Clinic, Rochester, Minn (D.L.B.). Received June 15, 2019; revision requested July 9; final revision received July 23; accepted August 8. **Address correspondence to** D.L. (e-mail: [dlevine@bidmc.harvard.edu](mailto:dlevine@bidmc.harvard.edu)).

Conflicts of interest are listed at the end of this article.

See also the editorial by Grant in this issue.

Radiology 2019; 293:359–371 • <https://doi.org/10.1148/radiol.2019191354> • Content codes: 

This multidisciplinary consensus update aligns prior Society of Radiologists in Ultrasound (SRU) guidelines on simple adnexal cysts with recent large studies showing exceptionally low risk of cancer associated with simple adnexal cysts. Most small simple cysts do not require follow-up. For larger simple cysts or less well-characterized cysts, follow-up or second opinion US help to ensure that solid elements are not missed and are also useful for assessing growth of benign tumors. In postmenopausal women, reporting of simple cysts greater than 1 cm should be done to document their presence in the medical record, but such findings are common and follow-up is recommended only for simple cysts greater than 3–5 cm, with the higher 5-cm threshold reserved for simple cysts with excellent imaging characterization and documentation. For simple cysts in premenopausal women, these thresholds are 3 cm for reporting and greater than 5–7 cm for follow-up imaging. If a cyst is at least 10%–15% smaller at any time, then further follow-up is unnecessary. Stable simple cysts at initial follow-up may benefit from a follow-up at 2 years due to measurement variability that could mask growth. Simple cysts that grow are likely cystadenomas. If a previously suspected simple cyst demonstrates papillary projections or solid areas at follow-up, then the cyst should be described by using standardized terminology. These updated SRU consensus recommendations apply to asymptomatic patients and to those whose symptoms are not clearly attributable to the cyst. These recommendations can reassure physicians and patients regarding the benign nature of simple adnexal cysts after a diagnostic-quality US examination that allows for confident diagnosis of a simple cyst. Patients will benefit from less costly follow-up, less anxiety related to these simple cysts, and less surgery for benign lesions.

© RSNA, 2019

Online supplemental material is available for this article.

The Society of Radiologists in Ultrasound (SRU) convened a multidisciplinary consensus conference in 2009 to make recommendations for adnexal cyst follow-up. Our goal was to define characteristics of benign adnexal cysts to reduce surgical evaluation and imaging follow-up (1). Commensurate with the overall goal of the Choosing Wisely campaign to reduce unnecessary imaging (2), the consensus recommendations published in 2010 established size thresholds for benign-appearing cysts not requiring follow-up (Table E1 [online]). This effort was successful. One study (3) found that the guidelines reduced overall US utilization because of decreased radiologists' recommendations for follow-up of benign-appearing cysts, while another study (4) validated the guideline in mostly symptomatic women and suggested that the utility of the SRU framework was not limited to asymptomatic cysts.

Recent large studies (5–7) showing no increased risk of malignancy in women with simple adnexal cysts irrespective of cyst size justify reevaluation of the 2010 SRU guidelines,

specifically to address the follow-up and reporting of simple cysts. The consensus group met by teleconference from February through June 2019 under the auspices of the SRU, and consisted of 20 experts in US, gynecologic imaging, gynecologic pathology, gynecologic oncology, epidemiology, radiology, and minimally invasive surgery (Table E2 [online]). Before starting the phone discussions, three of the author group (D.L., M.D.P., D.L.B.) reviewed the literature in Tables E3 and E4 (online) (with each article having at least two reviewers) and made the summary information from the literature, along with reasons for exclusions of studies, available to the larger group. The pathology expert (J.H.) did not participate in votes regarding clinical recommendations. We used a modified Delphi model for discussion and voting cycles among experts. In this article, we use the term *strong consensus* when there was greater than or equal to 90% agreement among the 19 voting panelists ( $\geq 18$  individuals), *moderate consensus* for recommendations based on greater than or equal to

## Abbreviation

SRU = Society of Radiologists in Ultrasound

## Summary

In postmenopausal women, simple cysts greater than 1 cm in size should be described but do not need follow-up imaging unless they are greater than 3–5 cm, using the higher threshold for exceptionally well-visualized simple cysts. These thresholds are greater than 3 cm and greater than 5–7 cm in premenopausal women.

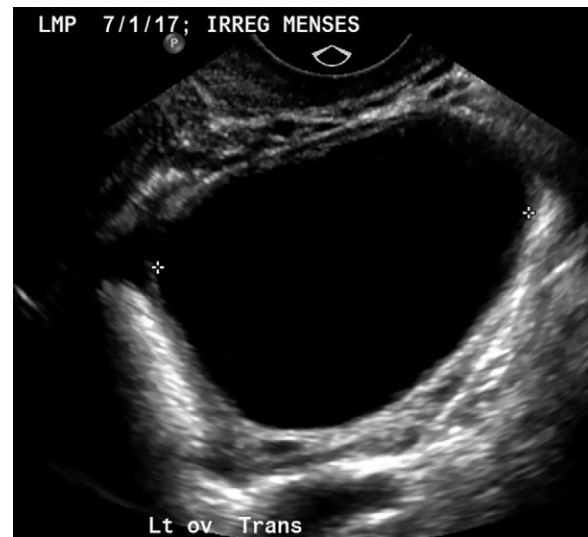## Key Results

- A woman with an asymptomatic, isolated, simple adnexal cyst that has been well visualized has no difference in cancer risk compared with a woman without such a cyst irrespective of menopausal status or cyst size.
- In postmenopausal women, simple cysts greater than 1 cm in size should be described but do not need follow-up imaging unless they are greater than 3–5 cm, using the higher threshold for exceptionally well-visualized simple cysts.
- In premenopausal women, simple cysts greater than 3 cm in size should be described but do not need follow-up imaging unless they are greater than 5–7 cm, using the higher threshold for exceptionally well-visualized cysts.
- A cyst can only be diagnosed as simple if it has been fully evaluated and clearly meets imaging criteria for a simple cyst: anechoic, unilocular, a thin smooth wall, and no internal flow. If there is any uncertainty about whether a cyst is simple, then shorter-interval (2–6 months) follow-up is recommended. Otherwise, if the simple cyst is above the previously described size thresholds, then follow-up imaging is recommended to assess growth (6–12 months).
- If a simple cyst is smaller (and still simple) on any follow-up sonogram, then continued follow-up is unlikely to be of value. Simple cysts that are stable at first follow-up are likely nonneoplastic cysts, but follow up at 2 years helps to confirm this impression. Simple cysts that increase in size are likely cystadenomas; additional follow-up at 2 years helps define growth rate, with subsequent clinical follow-up as needed.

75%–90% agreement (15–17 individuals), and *majority opinion* when 10–14 voters supported a recommendation.

## Definition of Simple Cyst

A simple cyst is a round or oval anechoic fluid collection with smooth thin walls, no solid component or septation, and no internal flow by using color Doppler imaging (Fig 1). When describing cysts in the pelvis, we use the term *adnexal* if the cyst is not clearly arising from the ovary. *Paraovarian* and *paratubal* cysts (terms which are often used interchangeably) are epithelium-lined cysts in the adnexa adjacent to the ovary and/or fallopian tube. They arise from Mullerian or Wolffian ducts or peritoneal mesothelial lining. At times, when seen separate from the ovary, it is possible to describe paraovarian and paratubal cysts as *nonovarian*. This is helpful because simple paraovarian and paratubal cysts are known to have a very low incidence of malignancy (8–10). If a simple cyst is clearly paraovarian (regardless of size), then follow-up is not required but may be performed at the discretion of the referring clinician. The use of transvaginal sonography is usually best but transabdominal imaging may be helpful with high or laterally located cysts or if transvaginal sonography is declined. Three orthogonal measurements should be obtained with little pressure on the



**Figure 1:** Grayscale image shows 5.1-cm simple cyst (calipers) in a 25-year-old woman with irregular menses. Cyst resolved at 6-week follow-up.

US probe. Although all three should be reported, the largest single diameter is used for management and decisions regarding need for subsequent US. Color Doppler is utilized to help identify solid elements and to distinguish hypoechoic solid lesions mischaracterized as cysts (1,11). Accurate characterization of a simple cyst is key for a confident exclusion of malignancy. A cine clip is helpful when the interpreting physician does not perform the study. Cine clips are also useful for comparison with subsequent studies, to ensure similarity of repeat measurement technique on a follow-up scan. Three-dimensional reconstructed volumes can help assess small areas of wall irregularity in larger cysts.

Simple cysts generally demonstrate posterior acoustic enhancement, but this is not always present (especially in smaller cysts) with compound imaging, which is frequently available on modern imaging equipment (12). Therefore, there no longer is a requirement that a simple cyst demonstrate acoustic enhancement when compound imaging is utilized, but there should be no attenuation of sound. When posterior acoustic enhancement is not present, then attention should be paid to Doppler imaging to ensure there is not a hypoechoic solid lesion masquerading as a cyst.

## Risk of Malignancy Associated with Simple Cysts

Simple cysts are common in premenopausal women, most representing follicles and corpus luteal cysts. In early menopause (first 2 years after last menstrual period), cysts may represent residual functional activity. In a large series of postmenopausal women, cysts were reported in 14% of initial US examinations (6). The incidence of new simple cysts at 1-year follow-up was 8%, and 32% had no cyst 1 year later. Other studies have confirmed the transient nature of many postmenopausal cysts (11,13), including an autopsy study (14) that found that “small ( $\leq 50$  mm) benign adnexal cysts... are so common in postmenopausal women that their presence may be regarded as normal.”

Recent large studies suggest that ovarian malignancy risk in women with simple cysts is similar to the overall population risk (5,15). This is concordant with advancements in understanding the pathogenesis of invasive serous cystadenocarcinomas, which are now known to largely originate from the fallopian tube rather than the ovary (16), reducing the likelihood that simple ovarian cysts represent precursors to malignancy (5,15).

### Limitations of Existing Literature

Confidence that an adnexal cyst can be characterized as being simple at US is a fundamental consideration when assessing the literature. Older studies based on transabdominal technique (17–23) and studies where it is unclear if all cysts underwent transvaginal sonography (24–28) were excluded from our analysis because of a higher risk of misclassification (29,30). Furthermore, in our review of existing literature (Tables E3, E4 [online]), we excluded investigations that assessed unilocular cysts but did not specify absence of internal echoes, or that grouped simple cysts with other benign ovarian cysts (13,31–42). A unilocular cyst is not a simple cyst if it has internal echoes or small wall irregularities. Data from the International Ovarian Tumor Analysis, or IOTA, group and the University of Kentucky group suggest that unilocular cysts have a less than 1% risk of malignancy (30,43). Simple cysts are a subset of unilocular cysts and are expected to have an even lower risk (if any) of malignancy. We also did not include screening studies in high-risk populations (44) because the SRU guidelines are not intended for high-risk populations in which imaging surveillance and surgical management of ovarian cysts are highly influenced by the pretest probability of cancer.

Of the remaining studies, limitations include the following: selection bias, most commonly for retrospective surgical cohorts in which the prevalence of malignancy is higher than clinical populations of women with adnexal masses (45,46), or screening trials that may not be generalizable to clinical populations (6,7,41); uncertainty if the sonographically identified simple cyst corresponds to the pathologically identified carcinoma; possible misclassification of simple cysts as a result of older imaging equipment or scanning protocols (28); and utilization of outdated pathologic terminology.

### Studies Based on Surgical Cohorts Overestimate Risk

The studies in Table E3 (online) evaluated patients undergoing surgery who generally were already known to have persistent cysts. Despite the fact that these studies have a bias toward detecting a higher risk of malignancy than in the general population (30,47), the majority of these studies found a malignancy rate of 0% for simple cysts (with sample sizes of seven to 221 patients) (25,30,45,46,48–55). A meta-analysis (56) that included many of the studies in Table E3 (online) found 20 malignancies (including eight borderline tumors) among 2290 simple cysts removed surgically (0.9%; 95% confidence interval: 0.57%, 1.35%). The invasive cancer rate was 0.5%. While two studies in Table E3 (online) show malignancy rates as high as 6% (46) and 9.8% (45), these studies are dated (from 1995 and 1998), with small sample size (16 and 112, respectively), one of which did not use standard image acquisition or docu-

mentation. Furthermore, the 2014 update to the World Health Organization classification system redefined the histologic definition of borderline tumors (57,58) in such a way that some cysts in the above studies that were originally classified as borderline malignancies would now be classified as benign cystadenomas. Overall, it is clear from the studies based on surgical cohorts that the risk of malignancy in simple cysts is at most very small.

### No Increased Risk of Cancer in Studies Based on Nonsurgical Cohorts

Table E4 (online) summarizes studies evaluating the risk of malignancy for simple cysts in nonsurgical cohorts (or populations where only some underwent surgery), including screening trials. While all studies are relatively small, five studies had no proven cancers for an incidence of cancer of 0% (patient sample size of 29–116) (29,59–62). Four studies had a risk of 0.03%–1% (patient sample size of 138–2217) (6,63–65).

Two large screening studies of 43 230 (7) and 72 093 (5) patients, respectively, found no significant increase in cancer risk among patients with and patients without simple cysts. These findings are consistent with the University of Kentucky report (41), in which 2700 women with unilocular cysts had an average of 6.3 years of follow-up with only 10 ovarian cancers detected, and none of these had a sonographic finding of a simple cyst (66). However, the generalizability of findings from screening populations to clinical populations is questionable given that in the case of screening, women are asymptomatic.

A prospective study by Suh-Burgmann (15) in 2016 evaluated ovarian cancer risk in a community-based cohort of 43 606 women undergoing pelvic US examinations with standardized reporting. They found the risk of cancer associated with simple cysts was 0.1% (95% confidence interval: 0.07%, 0.14%) to 0.2% (95% confidence interval: 0.05%, 0.3%), depending on their size.

A recent nested case-control study by Smith-Bindman (5) evaluated 1043 US examinations from women who were and were not diagnosed with cancer and extrapolated findings to their population of 72 093 women, and concluded that simple cysts of any size “should be considered normal findings and do not need surveillance.”

These studies confirm that the risk of cancer in simple cysts is small or nonexistent. Furthermore, even the small number of cancers reported to be associated with simple cysts may be spurious, because the presence of a simple cyst in a woman subsequently found to have ovarian cancer does not necessarily mean that the cancer originated from the cyst (Fig E1 [online]).

### Concepts Pertinent to Current Recommendations

Based on this literature review, the evidence is strong and consistent that simple adnexal cysts identified at US have negligible, if any, association with ovarian cancer (5,6,15). Education of referring clinicians and their patients is essential to reduce unnecessary follow-up imaging and surgery, because many patients (20.2% in one survey) think that a benign cyst increases the risk of ovarian cancer (67).

If simple cysts are commonly misunderstood by patients as potentially premalignant, then why and when should they be

reported? If there is no demonstrably increased relative risk of ovarian cancer with simple cysts, then why would US follow-up of any simple adnexal cyst be justified? What is the harm of follow-up of benign findings? Six concepts pertinent to these questions guided the panel's recommendations: (a) sonographic surveillance of benign findings may potentially increase surgical intervention and thereby unintended harm (68–71); (b) highlighting the presence of small commonly detected simple cysts can increase patient and provider anxiety; (c) this increased anxiety must be balanced by the need to document larger cysts, so that when patients are evaluated elsewhere there is an accurate context for comparison; (d) study quality (affected by body habitus, other masses such as fibroids, bowel gas, sonography equipment, and imager experience and confidence that the cyst is indeed simple) impacts the likelihood of sonographic mischaracterization of a simple adnexal cyst; (e) larger cyst size likely increases the possibility of mischaracterization; and (f) sonographic follow-up of some cysts may have clinical value for larger cysts that are more likely to be benign neoplasms or that bear a small risk of torsion or rupture (0.4% and 0.2%, respectively, in the IOTA 5 study) (72).

### Potential Harms of Surveillance US

The U.S. Preventive Services Task Force, or USPSTF, 2018 ovarian cancer screening guideline recommends against US screening for ovarian cancer stating “screening for ovarian cancer does not reduce ovarian cancer mortality. The USPSTF found adequate evidence that the harms from screening for ovarian cancer are at least moderate and may be substantial in some cases and include unnecessary surgery for women who do not have cancer” (69). USPSTF recommendations are based in part on long-term studies such as the Prostate Lung Colon Ovary cancer screening trial, where even after 16 years of follow-up, screening with transvaginal US showed no benefit (70). Similarly, the UK Collaborative Trial of Ovarian Cancer Screening showed no benefit in the primary analysis with multimodal screening (US and cancer antigen 125) (71).

US monitoring of simple cysts may lead to similar risks as ovarian cancer screening including patient anxiety, chance of incidental findings, and risk of surgical intervention. In the 2006 Agency for Healthcare Research and Quality “Management of Adnexal Mass” document (47), there were three deaths among 1500 surgeries for adnexal masses. Morbidity from surgery for benign adnexal cysts includes fever, urinary tract infection, urinary retention, bladder injury, wound infection, and cardiovascular and/or pulmonary complications with the incidence of complications ranging from 3.1% to 15% in screening trials (68,71,73).

### Reporting Simple Cysts When Not Recommending Follow-up

Describing simple adnexal cysts can have value even when follow-up is not recommended; it provides documentation in the event a patient seeks future care elsewhere, so that another provider does not mistakenly believe a cyst is new merely because it was not previously reported. However, this benefit must be balanced against the potential anxiety and unintended surveillance that can be generated by description of these inconsequential

cysts. The panel's recommendations are shown in Figures 2–4. There was strong consensus to explicitly describe an ovary as “normal” when harboring simple cysts less than or equal to 1 cm in postmenopausal women and simple cysts less than or equal to 3 cm in largest diameter in premenopausal women. The majority opinion was that if simple cysts less than or equal to 3 cm were mentioned in premenopausal women, in addition to labeling the ovary as normal, the use of the term *follicle* instead of *simple cyst* could decrease potential patient anxiety. This description is left up to the provider and the practice in which they work, because while the majority of simple cysts in this size range are physiologic, they are not all follicles.

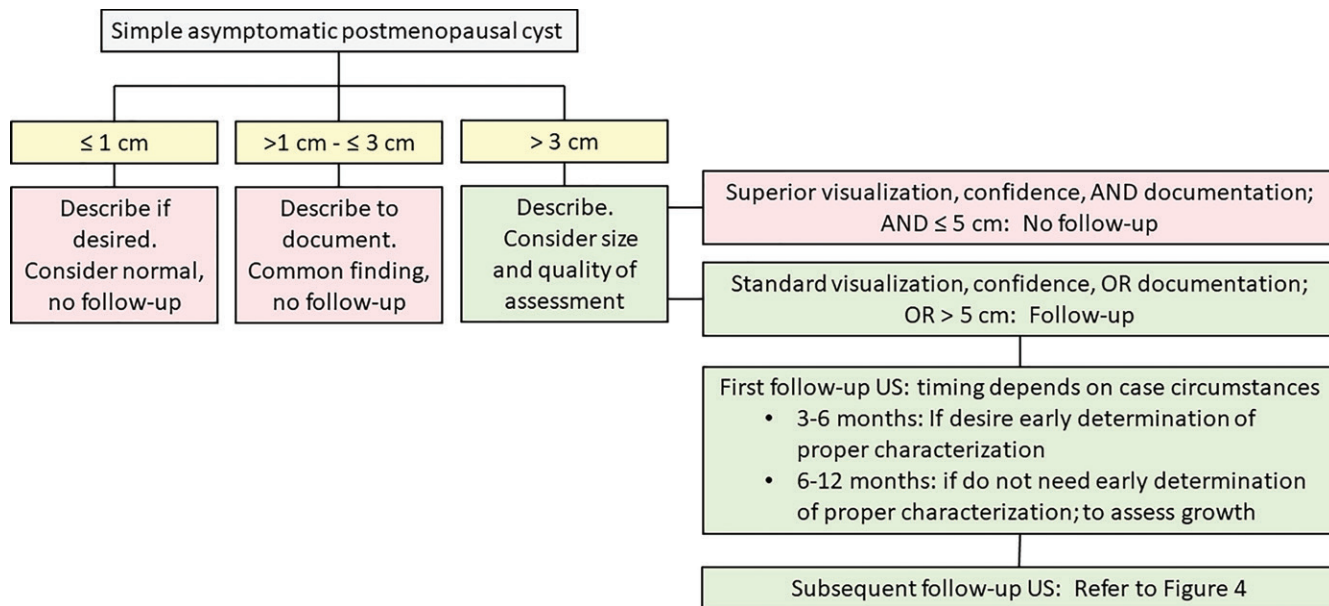
### Risk of Cyst Mischaracterization

In selecting criteria to determine which simple adnexal cysts might benefit from sonographic surveillance and when that surveillance should occur, the accuracy of characterization is important to consider. US is operator dependent and errors in obtaining accurate images or interpretation of those images occur. Sonographic follow-up can confirm accurate initial characterization of a simple adnexal cyst providing more than one opportunity to assess a lesion. Reasonable factors to consider when deciding which patients would benefit most from recharacterization and follow-up of a simple cyst include scan quality (equipment and patient factors, image documentation, and imager experience) and cyst size (because ovarian cystic cancers are larger than nonneoplastic cysts and a small papillary formation might more easily be overlooked within a larger cyst) (48).

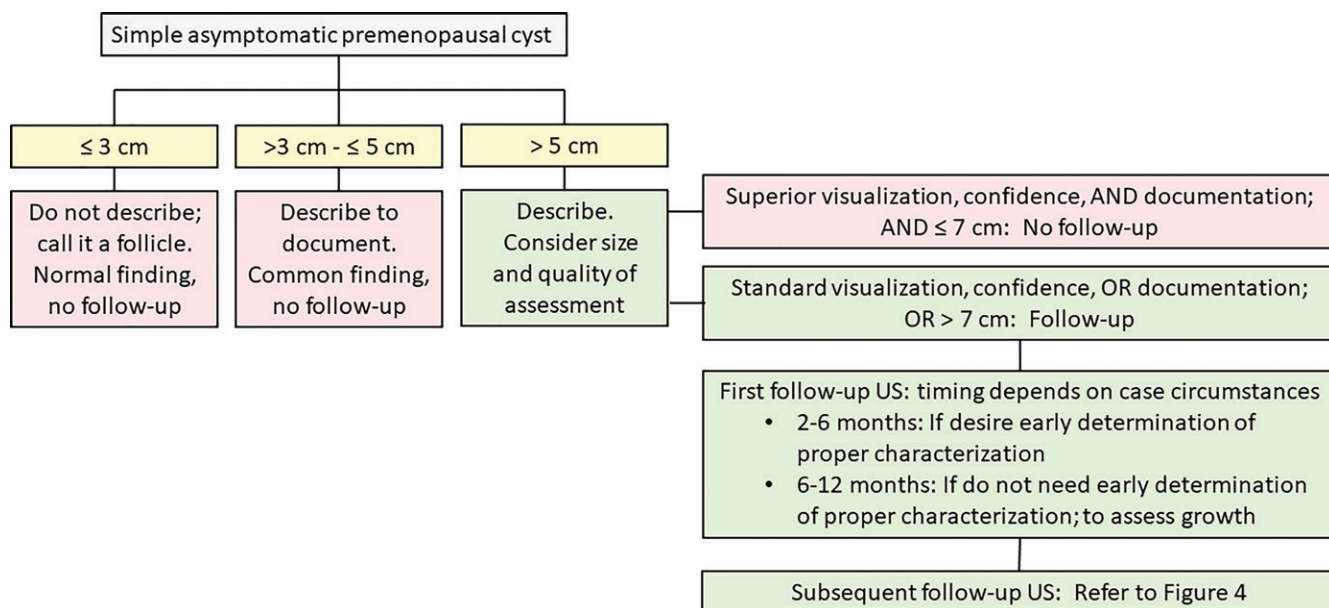
A high-quality sonogram is a prerequisite for the decision to not recommend further evaluation of simple cysts (74). Participating facilities should meet the following basic standards (75): (a) oversight is provided by an appropriately trained physician working in an accredited department with certified sonographers (if the physician is not the one scanning); (b) scans are performed by providers and interpreted by physicians, all of whom meet at least minimum training and/or certification standards for US, including transvaginal sonography; (c) scanning equipment includes transvaginal sonography capabilities with color Doppler imaging and permits adequate visualization of the internal contents of cysts; and (d) facilities maintain quality assurance programs. However, in making recommendations regarding which cysts would benefit most from follow-up, the group consensus was that higher size thresholds were justified when there was superior visualization (due to patient-specific factors), confidence in diagnosis (physician factor), and documentation (consisting of cine clips). Some clinicians also felt that three-dimensional imaging is helpful in assessing the wall of cysts. Having a follow-up US performed by a different physician with expertise in gynecologic US may also be helpful.

### Cyst Size

Errors related to incomplete imaging may be more likely with larger cysts, but the optimal size threshold for defining increased risk remains uncertain (13,30,48). Without strong evidence for a size threshold conferring a higher risk of mischaracterization, the consensus was to use size thresholds that overlapped Ovarian-Adnexal Reporting and Data System, or



**Figure 2:** Flowchart shows recommendations for postmenopausal simple asymptomatic cyst management at first study.



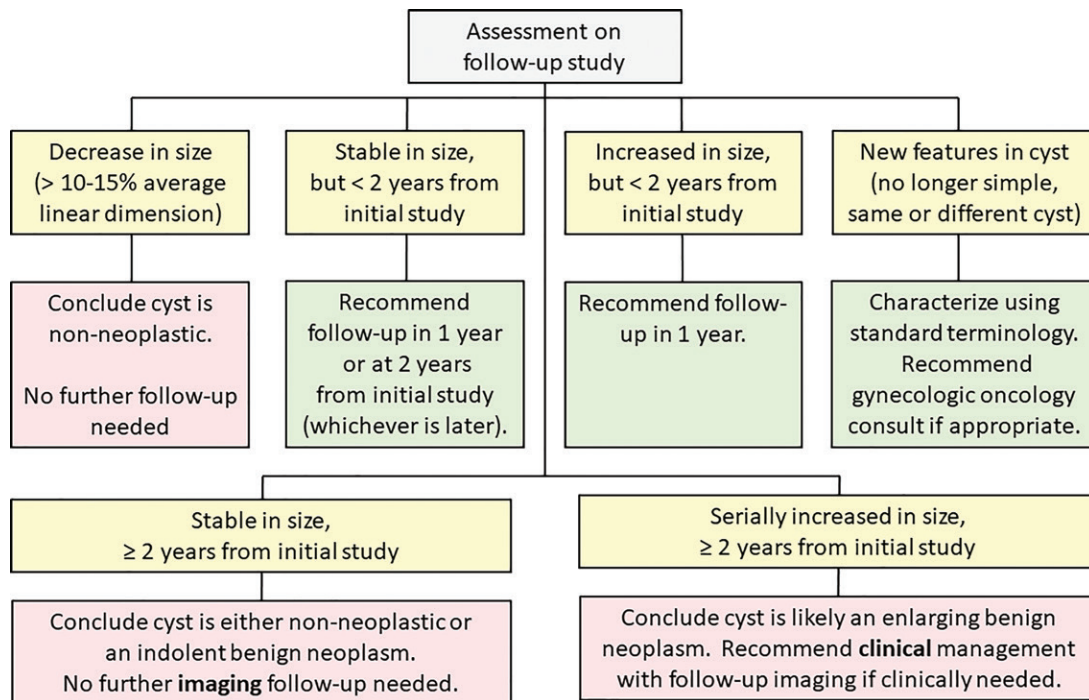
**Figure 3:** Flowchart shows recommendations for premenopausal asymptomatic simple cyst management at first study.

O-RADS, recommendations for cysts with suboptimal characterization (76) (Table E1 [online]).

### Timing, Duration, and Imaging Used during Follow-Up

Properly characterized simple adnexal cysts should represent either nonneoplastic cysts or benign neoplasms. The majority of nonneoplastic simple cysts in premenopausal women and many in the early postmenopausal women (within 2 years of the final menstrual period) are hormonally driven functional cysts that will resolve or become smaller within 3 months. Benign neoplasms can enlarge over time, whereas nonneoplastic cysts are more likely to be stable, wax and

wane, or resolve completely. Simple cysts, irrespective of size, should not cause pain during imaging. If imaging a cyst causes pain, then this should be reported to the referring clinician who can then assess the patient to determine if intervention is required. Suh-Burgmann (77), found that nonsimple cysts later found to be malignant developed suspicious features within 7 months of initial scans (78). When timing the follow-up, it is important to allow intervals long enough for resolution, yet short enough to prevent possible progression of malignancy because of initial mischaracterization. Although large simple cysts are still likely to be benign neoplasms, progressive enlargement may prompt



**Figure 4:** Flowchart shows recommendations for imaging after follow-up of simple asymptomatic cyst in either pre- or postmenopausal women.

surgery because enlarging masses are more likely to become symptomatic. The patient's age and clinical profile may also predispose toward surgical intervention.

Because a simple cyst is likely benign, the group consensus was to obtain the initial follow-up study in a range from 3–12 months, using a 3–6-month time frame if providers and/or patients had concerns regarding potential cyst mischaracterization or if this cyst has a high likelihood of resolving (as is the case for premenopausal women). O-RADS uses a time frame for repeat study of 2–3 months for premenopausal women (73), and that is certainly reasonable for short-interval follow-up if patient or physician anxiety leads to a request for an earlier study to document resolution. Therefore, in premenopausal women we set a lower limit for follow-up of 2 months. A longer initial follow-up interval of 6–12 months would be preferable if the cyst is thought to be well seen and the primary objective is to evaluate the growth rate of the cyst. At follow-up US, if a simple cyst resolves or decreases in size and the patient remains asymptomatic, then further imaging is not indicated.

There was less consensus for best practice if follow-up US revealed increasing or stable size of an asymptomatic well-characterized simple cyst. Theoretically, the already very low risk that a simple cyst is a mischaracterized malignancy is reduced by the first follow-up study showing that the cyst remains simple. Based on this, some panelists took the position that the risks from further US surveillance are greater than any benefit that accrues from continued US surveillance of a possible cystadenoma, and that a simple cyst that is likely a cystadenoma could be reasonably managed with periodic clinical follow-up (assessing patient symptoms, physical examination, and risk factors) without recommending “routine” yearly US. Other panelists took the position that at least 2 years (initial examination and

two follow-up examinations spread over 2 years) of imaging follow-up was needed to assure a stable size because measurement variability might underestimate or overestimate true growth of a cyst at a first follow-up study. If a simple cyst is stable in size for 2 years, then it is likely a nonneoplastic cyst and might not require further periodic clinical follow-up; if a simple cyst grows over 2 years, then it is likely a cystadenoma and might benefit from further clinical follow-up.

Neither the reproducibility of ovarian cyst measurement by using US nor the growth rate of benign ovarian cystadenomas have been well studied. Recommendations vary from using a change in largest diameter of 1 cm (65) to using a 20% change in cyst volume (64). However, there are no data to support either study criterion as a reliable indicator of cyst size change. The majority of the panel felt that a 10%–15% increase in largest diameter represented growth of the simple cyst (of note, if one assumes an ellipsoid, then this corresponds to a cyst volume change of 33%–52%).

In assessing growth rate, measurement variability will introduce more error in estimated growth rate when the interval between assessments is small. Measurement variability is also more likely when conclusions are based on only the largest diameter. Establishing criteria for cyst enlargement is more important than resolution because any meaningful decrease in size is not consistent with a neoplasm, regardless of the time interval, even if the cyst never completely resolves. Additionally, if the same cyst changes shape at follow-up US, then it may be difficult to rely on a comparison of maximum diameter and in such a situation comparison of all three diameters or cyst volume may be better for assessing change.

The role of MRI in triaging masses with indeterminate US findings was discussed by the consensus group. In a retrospective study by Maturen (4), using MRI for cysts greater than

**Table 1: Postmenopausal Simple Cyst Recommendations: SRU Consensus Conference Standardized Wording for Reports, Impressions, and Recommendations for Clinically Inconsequential Asymptomatic Postmenopausal Simple Cysts**

Observation of Simple Cyst(s) in the Adnexa (Suspected Ovarian Except Where Indicated), Largest Cyst Diameter*	Report	Impression	Recommendation	Level of Evidence Regarding Impact on Malignant Outcomes <sup>†</sup>	Level of Support Based on Clinical Experience/Opinion Regarding Potential Impact on Clinical Outcomes Other Than Malignancy <sup>†</sup>	Overall Level of Consensus for Recommendation <sup>†</sup>
≤1 cm	Description not needed	Normal ovaries/adnexa	Normal, no follow-up	A	A	Strong consensus
>1 cm to ≤3 cm	Describe in report, giving largest simple cyst diameter. <sup>†</sup>	Benign inconsequential finding	Clinically inconsequential finding. No follow-up needed.	A	A	Strong consensus
>3 to ≤5 cm	Describe in report, giving all simple cyst diameters, but making recommendation from largest cyst diameter and quality of visualization and documentation.*	Benign simple cyst. Clinically inconsequential finding	Generally will require follow-up examination. However, if exceptionally well-visualized and characterized, with excellent documentation, and imager confidence by an experienced US practitioner, no follow-up imaging is needed. If any concern, or if imager is less confident in diagnosis, then follow-up is recommended. Follow up in 3–6 months for characterization or 6–12 months for growth assessment.	A if no follow-up, C if follow-up	C <sup>‡</sup>	Majority opinion
>5 cm	Describe in report, giving all simple cyst diameters, but making recommendation from largest cyst diameter.	Benign simple cyst	Follow up in 3–6 months for characterization or 6–12 months for growth assessment.	C	B	Strong consensus
Follow-up evaluation, decreased in size	Describe in report, giving largest simple cyst diameter, and indicate cyst is smaller.	Benign simple cyst; decrease in size excludes neoplasm. <sup>§</sup>	No further follow-up is needed.	A	A	Strong consensus
Follow-up evaluation, similar in size	Describe in report, giving largest simple cyst diameter, and indicate similar size.	Benign simple cyst	Follow-up at 2 years since initial study to assess if slowly growing. If still stable, then no further imaging will be needed unless clinically indicated.	C	B	Moderate consensus
Follow-up evaluation, increased in size	Describe in report, giving largest simple cyst diameter, and indicate change in size.	An enlarging simple cyst is most likely a benign neoplasm.	Suggest one further follow-up in 1 year to assess any further changes in size. After that, follow-up will be clinically managed.	C	A	Strong consensus
Previously simple cyst develops wall papillary projections or solid elements or irregular septation(s)	Describe in report, giving largest cyst diameter, and articulating all morphologic changes.	The observed changes in the adnexal cyst increase concern for malignancy.	If changes are unequivocally present and within original cyst, then recommend consultation with Gynecologic Oncology. If equivocal, then repeat short-interval US, second-opinion US, or MRI could be helpful.	A	A	Strong consensus

Table 1 (continues)

**Table 1 (continued): Postmenopausal Simple Cyst Recommendations: SRU Consensus Conference Standardized Wording for Reports, Impressions, and Recommendations for Clinically Inconsequential Asymptomatic Postmenopausal Simple Cysts**

Observation of Simple Cyst(s) in the Adnexa (Suspected Ovarian Except Where Indicated), Largest Cyst Diameter*	Report	Impression	Recommendation	Level of Support		
				Level of Evidence Regarding Impact on Malignant Outcomes†	Level of Support Based on Clinical Experience/Opinion Regarding Potential Impact on Clinical Outcomes Other Than Malignancy†	Overall Level of Consensus for Recommendation†
Simple paraovarian or paratubal cyst(s)	Describe in report, clearly indicating that the simple cyst does not arise from the ovary.	Benign extraovarian simple cyst	No further follow-up is needed.	A	A	Strong consensus
Adnexal cyst likely simple but not satisfactorily characterized with US	Describe in report, indicating any reasons limiting characterization.	Probably simple cyst is not optimally characterized.	Consider short-interval follow-up US, second-opinion US, or MRI (any of these in <3 months) to improve cyst characterization.	C	A	Strong consensus

Note.—This table is meant for asymptomatic patients or patients with symptoms attributable to the visualized cyst, and not at elevated genetic risk or without substantial family history and no other evidence of cancer such as elevated cancer antigen 125. Patients may develop symptoms if cyst size enlarges or cyst undergoes torsion. In cases where patient has symptoms attributable to cyst, then clinical management supersedes the recommendations in this table. Simple cyst: well-visualized, thin-walled, anechoic, no solid elements, no internal vascular flow. SRU = Society of Radiologists in Ultrasound.

\* Largest cyst diameter is measured when cyst is as round as possible. Best characterization of internal architecture of a cyst may require pressure with the transducer that makes a cyst more ovoid. Both types of imaging are important (to measure and to characterize the cyst).

† Since strong published evidence was lacking for most of our conclusions, we defaulted to a letter grade (A = strong, B = moderate, C = weak).

One grade was based on literature evidence. In general, since the literature has limited data regarding benefit of follow-up of simple cysts, the evidence was strong (grade A) for those recommendations with no follow-up and weak (grade C) for those recommendations with follow-up (except where cyst was not simple or was not adequately characterized). Another grade was based on clinical experience/opinion (A = strong support for the recommendation, B = moderate support, C = poor support). The final column gives levels of consensus for the recommendations (graded as strong consensus, 18–19 votes; moderate consensus, 15–17 votes; majority opinion, 11–14 votes) (there were 19 voting members on the committee).

‡ Disagreement was if a tiered system was beneficial or if a single threshold of 3 cm should be used.

§ However, if ovary and cyst are not seen, then it must be acknowledged that a small cyst could still be present but missed.

7 cm rather than surgical intervention in a referral population of women with adnexal masses (malignancy rate of 10%) theoretically would have potentially reduced the number of surgical evaluations of benign cysts by 89.1% (82 of 92 benign cysts). However, this study did not show evidence that cyst size contributed to an inaccurate US diagnosis, and it also assumed that all large cysts at US would go to surgery if MRI had not been performed. Our group agreed that MRI is most likely to be helpful when the physician interpreting the sonographic images is less confident in the sonographic characterization of the cyst, based on case-specific limitations.

### Updated SRU Consensus Conference Statements and Recommendations

Unnecessary follow-up of simple cysts increases the chance of surgical intervention as slow or uncertain growth can lead to recommendations for surgical removal even in the absence of malignant findings. Once an adnexal cyst demonstrates sonographic features indicating a negligible risk of malignancy, imaging follow-up may still be reasonable for those cysts large enough to merit surveillance to distinguish a growing benign

neoplasm from a nonneoplastic cyst. However, it is also reasonable to rely on clinical follow-up alone (patient symptoms and physical examination) once a cyst has been well-characterized as simple, with US follow-up used as the clinician feels indicated. A thorough patient assessment is required to make specific recommendations for surgical intervention based on careful review of a patient's symptoms, age, medical profile, and US findings.

Table 1 (postmenopausal) and Table 2 (premenopausal) outline our consensus (with evidence ratings) regarding the reporting, impression, and recommendations for clinically inconsequential simple cysts. These recommendations do not apply when cyst-attributed symptoms merit clinical action or in patients with increased risk of ovarian cancer (44).

### Limitations

It should be stressed that these guidelines are for asymptomatic simple cysts and do not apply to patients at increased risk for ovarian cancer. This document details recommendations regarding simple cysts only. The recommendations for other benign cysts, probably benign cysts, and malignant cysts can be found in our original consensus document (1).



**Table 2: Premenopausal Simple Cyst Recommendations: SRU Consensus Conference Standardized Wording for Reports, Impressions, and Recommendations for Clinically Inconsequential Asymptomatic Premenopausal Simple Cysts**

Observation of Simple Cyst(s), Largest Cyst Diameter*	Report	Impression	Recommendation	Level of Support		Overall Level of Consensus for Recommendation†
				Level of Evidence Regarding Impact on Malignant Outcomes†	Based on Clinical Experience/Opinion Regarding Potential Impact on Clinical Outcomes Other Than Malignancy†	
≤3 cm	Description not needed. If described, consider use of word <i>follicle</i> rather than <i>cyst</i> (76).	Normal ovaries/adnexa	Normal, no follow-up	A	A	Strong consensus
>3 cm to ≤5 cm	Indicate presence of simple cyst(s), and largest cyst diameter.	Benign finding in the physiologic size range	No follow-up needed	A	A	Strong
>5 to ≤7 cm	Describe in report, giving all simple cyst diameters, but making recommendation from largest cyst diameter and quality of visualization and documentation.*	Benign simple cyst. Clinically inconsequential finding	Generally will require follow-up examination. However, if exceptionally well-visualized and characterized, with excellent documentation, and imager confidence by an experienced US practitioner, then no follow up imaging is needed. If any concern, or if imager is less confident in diagnosis, then follow-up is recommended. Follow up in 2–6 months for resolution/characterization or 6–12 months for growth rate assessment.	A if no follow-up, C if follow-up	C‡	Majority opinion
> 7 cm	Describe in report, giving all simple cyst diameters, but making recommendation from largest cyst diameter.	Benign simple cyst	Follow up in 2–6 months for resolution/characterization or 6–12 months for growth rate assessment.	C	A	Strong consensus
Follow-up evaluation (simple cyst initially >5 cm), decreased in size	Describe in report if cyst not resolved, giving all simple cyst diameters, but making recommendation from largest cyst diameter.	Benign inconsequential finding; decrease in size excludes neoplasm§	No further follow-up is needed	A	A	Strong consensus
Follow-up evaluation (simple cyst initially >5 cm), similar in size	Describe in report, giving all simple cyst diameters, but making recommendation from largest cyst diameter, and indicate similar size.	Benign simple cyst. A simple cyst with stability over 12 or more months is most likely nonneoplastic or a very slow growing benign neoplasm; one further imaging test to document stability may be helpful. If no growth, then no further follow-up will be needed.	Follow up at 2 years after initial study to understand growth rate.	C	B	Moderate consensus

Table 2 (continues)

**Table 2 (continued): Premenopausal Simple Cyst Recommendations: SRU Consensus Conference Standardized Wording for Reports, Impressions, and Recommendations for Clinically Inconsequential Asymptomatic Premenopausal Simple Cysts**

Observation of Simple Cyst(s), Largest Cyst Diameter*	Report	Impression	Recommendation	Level of Support		
				Level of Evidence Regarding Impact on Malignant Outcomes†	Based on Clinical Experience/Opinion Regarding Potential Impact on Clinical Outcomes Other Than Malignancy†	Overall Level of Consensus for Recommendation‡
Follow-up evaluation (simple cyst initially >5 cm), increased in size	Describe in report, giving all simple cyst diameters, but making recommendation from largest cyst diameter.	An enlarging simple cyst is most likely a benign neoplasm; follow-up imaging strategy is based on clinical management.	Suggest one further follow-up in 1 year to any further changes in size.	C	A	Strong consensus
Previously simple cyst develops wall papillary projections or solid elements or irregular septation(s)	Describe in report, giving all cyst diameters, and articulating morphologic changes.	The observed changes in the adnexal cyst increase concern for malignancy	If changes are unequivocally present and within original cyst, recommend consultation with Gynecologic Oncology. If equivocal, then repeat short-interval US, second-opinion US, or MRI could be helpful.	A	A	Strong consensus
Simple paraovarian or paratubal cysts	Describe in report giving maximal simple cyst diameter, clearly indicating that the cyst does not arise from the ovary.	Benign extraovarian simple cyst	No further follow-up is needed.	A	A	Strong consensus
Adnexal cyst likely simple but not satisfactorily characterized at US	Describe in report giving all cyst diameters, indicating any reasons limiting characterization.	Probably simple cyst is not optimally characterized; short-interval follow-up US or second-opinion US, or MRI might improve cyst characterization.	Consider short-interval follow-up US, second-opinion US, or MRI (any of these in <3 months).	C	A	Strong consensus

Note.—This table is meant for asymptomatic patients or patients with symptoms attributable to the visualized cyst, and not at elevated genetic risk or without substantial family history and no other evidence of cancer such as elevated cancer antigen 125. Patients may develop symptoms if cyst size enlarges or cyst undergoes torsion. In cases where patient has symptoms attributable to cyst, then clinical management supersedes the recommendations in this table. Simple cyst: well-visualized, thin-walled, anechoic, no solid elements, no internal vascular flow. SRU = Society of Radiologists in Ultrasound.

\* Largest cyst diameter is measured when cyst is as round as possible. Best characterization of internal architecture of a cyst may require pressure with the transducer that makes a cyst more ovoid. Both types of imaging are important (to measure and to characterize the cyst).

† Since strong published evidence was lacking for most of our conclusions, we defaulted to a letter grade (A = strong, B = moderate, C = weak). One grade was based on literature evidence. In general, since the literature has limited data regarding benefit of follow-up of simple cysts, the evidence was strong (grade A) for those recommendations with no follow-up and weak (grade C) for those recommendations with follow-up (except where cyst was not simple or was not adequately characterized). Another grade was based on clinical experience/opinion (A = strong support for the recommendation, B = moderate support, C = poor support). The final column gives levels of consensus for the recommendations (graded as strong consensus, 18–19 votes; moderate consensus, 15–17 votes; majority opinion, 11–14 votes) (there were 19 voting members on the committee).

‡ Disagreement was if a tiered system was beneficial or if a single threshold of 5 cm should be used.

§ However, if ovary and cyst are not seen, it must be acknowledged that a small cyst could still be present but missed.

### Evidence Ratings

We were interested in evidence for two different groups of outcomes: follow-up is likely or unlikely to improve outcomes related to malignancy (earlier detection, improved survival) and follow-up is likely or unlikely to improve other clinical outcomes (avoidance of surgery for benign disease,

avoidance of torsion, surgical complication rates, effects on fertility, patient anxiety).

In view of a less than 1% risk of malignancy associated with simple cysts, it is extremely unlikely that follow-up of any simple cysts will improve outcomes related to malignancy. For other clinical outcomes, there are no population-based studies (where

patient treatment reflects real-world practice and not prescribed by a research protocol), that address these questions, although the IOTA 5 data (72) suggests potential harm of follow-up due to increasing surgical rates. Prospective studies and screening trials (71,79) provide evidence of the likelihood of new incidental findings occurring during follow-up.

In regard to outcomes related to malignancy, all the recommendations for no follow-up are strongly supported by the evidence and were given a rating of A. The recommendations for follow-up are largely based on expert opinion, due to the absence of data specifically examining other clinical outcomes. Recommendations for follow-up took into consideration the concern for potential misclassification. We took into account the desire by some panelists for incremental change, rather than an abrupt transition to a symptom-based follow-up of simple cysts, which may be the recommendation in the future. Given the need to base the recommendations on both the evidence regarding malignancy risk and expert opinion, the overall recommendation rating follows a format modified from the GRADE system (80).

### Future Research

The committee identified specific gaps in knowledge as targets for future research:

1. Natural history of benign neoplasms.
  - a. Growth rate over time.
  - b. Likelihood of symptoms requiring surgery.
2. Impact of guidelines.
  - a. On practice (eg, how often do symptoms lead to imaging as opposed to guideline recommendations).
  - a. On patient outcomes.
  - b. On utilization.
3. US mischaracterization.
  - a. Rate of mischaracterization of simple cysts.
  - b. Factors influencing mischaracterization.
  - c. Whether specific training can reduce mischaracterization.
  - d. Registry of simple postmenopausal cysts < 3 cm and follow-up.
4. MRI.
  - a. Prospective evaluation of impact of MRI on outcomes for patients with large or enlarging simple cysts.

### Conclusion

In summary, sonographically identified simple adnexal cysts are benign findings. Multiple studies show that women with simple adnexal cysts have the same risk of ovarian cancer as do women without cysts. When a woman has a simple cyst and is subsequently diagnosed with ovarian cancer, that cancer most likely did arise from the simple cyst or is a consequence of cyst mischaracterization. The quality of the US study and interpretation—reflecting a combination of equipment, protocol, scanning skills, image documentation, and interpreter experience—can impact the risk of mischaracterization. Moreover, limited sonographic follow-up for cysts relatively large for menstrual status may be justified to reduce the risk of mischaracterization and to help predict which cysts are enlarging and likely to become symptomatic. To minimize inaccurate diagnoses, limited follow-up US is advised for postmenopausal

women with simple cysts greater than 3–5 cm (depending on the quality of the study and physician confidence in diagnosis) and premenopausal women with simple cysts greater than 5–7 cm. We hope these guidelines can be discussed with referring clinicians and added to structured reporting to standardize and limit follow-up of simple adnexal cysts.

These guidelines are meant for asymptomatic cysts, and should not be used in patients with painful cysts or in women at high genetic risk for ovarian cancer or other high-risk populations in whom imaging surveillance is influenced by the pretest probability of cancer. We hope that this report can help to reassure radiologists, clinicians, and patients about the benign nature of simple adnexal cysts. We expect that in the future, as scanning ability and technology continue to improve, the criteria for sonographic follow-up of simple adnexal cysts will become more relaxed. We also hope that by stressing the importance of quality US, the manner in which US is performed and interpreted may be improved and ultimately result in less patient anxiety and fewer surgeries for benign lesions.

**Author contributions:** Guarantors of integrity of entire study, D.L., M.D.P., E.J.S.B., E. Pavlik, E. Puscheck; study concepts/study design or data acquisition or data analysis/interpretation, all authors; manuscript drafting or manuscript revision for important intellectual content, all authors; approval of final version of submitted manuscript, all authors; agrees to ensure any questions related to the work are appropriately resolved, all authors; literature research, D.L., M.D.P., E.J.S.B., R.F.A., C.B.B., W.B., P.M.D., S.R.G., U.M.H., J.L.H., M.M.H., H.C.H., M.L.M., E. Pavlik, L.D.P., E. Puscheck, D.L.B.; clinical studies, B.R.B., E. Pavlik, L.D.P., E. Puscheck, R.S.B.; statistical analysis, E. Pavlik, R.S.B.; and manuscript editing, all authors.

**Disclosures of Conflicts of Interest:** D.L. disclosed no relevant relationships. M.D.P. Activities related to the present article: disclosed no relevant relationships. Activities not related to the present article: received payment for lectures including service on speakers bureaus from Los Angeles Radiological Society, Harbor Radiology Research, and World Class CME. Other relationships: disclosed no relevant relationships. E.J.S.B. disclosed no relevant relationships. R.F.A. Activities related to the present article: received support for travel for meetings for the study or other purposes from American College of Radiology and International Tumor Analysis Group. Activities not related to the present article: received payment for lectures including service on speakers bureaus from American Institute of Ultrasound in Medicine, Philips Healthcare Education, and Sociedad Mexicana de Radiología e Imagen; received payment for travel/accommodations/meeting expenses unrelated to activities listed from American Institute of Ultrasound in Medicine. Other relationships: disclosed no relevant relationships. B.R.B. Activities related to the present article: disclosed no relevant relationships. Activities not related to the present article: is an employee of Brigham and Women's Hospital; received payment for lectures including service on speakers bureaus from American Institute of Ultrasound in Medicine; receives royalties for three textbooks in print. Other relationships: disclosed no relevant relationships. C.B.B. disclosed no relevant relationships. W.R.B. Activities related to the present article: disclosed no relevant relationships. Activities not related to the present article: has grants/grants pending with the National Institutes of Health. Other relationships: disclosed no relevant relationships. B.G.C. Activities related to the present article: disclosed no relevant relationships. Activities not related to the present article: is the Ultrasound Commissioner for the American College of Radiology and sits on the Board of Chancellors; received payment for travel/accommodations/meeting expenses unrelated to activities listed from the American College of Radiology. Other relationships: disclosed no relevant relationships. P.M.D. disclosed no relevant relationships. S.R.G. Activities related to the present article: disclosed no relevant relationships. Activities not related to the present article: is a consultant for Cook OB/GYN and Cooper Surgical; serves on advisory board for AbbVie, AMAG, and Therapeutics MD; received equipment loan from GE Ultrasound. Other relationships: disclosed no relevant relationships. U.M.H. disclosed no relevant relationships. J.L.H. disclosed no relevant relationships. M.M.H. Activities related to the present article: disclosed no relevant relationships. Activities not related to the present article: is an employee of Einstein Healthcare Network. Other relationships: disclosed no relevant relationships. H.C.H. Activities related to the present article: disclosed no relevant relationships. Activities not related to the present article: is an author for UpToDate. Other relationships: disclosed no relevant relationships. M.L.M. Activities related to the present article: disclosed no relevant relationships. Activities not related to the

present article: received payment for development of educational presentations for Mayo website. Other relationships: disclosed no relevant relationships. **E. Pavlik** disclosed no relevant relationships. **L.D.P.** Activities related to the present article: disclosed no relevant relationships. Activities not related to the present article: institution receives research support from GE Medical Systems. Other relationships: disclosed no relevant relationships. **E. Puscheck** Activities related to the present article: disclosed no relevant relationships. Activities not related to the present article: is a consultant for Femsys; is employed by InVia Fertility; has grants/grants pending with AbbVie, Bayer, ObSeva, and NICHHD Reproductive Medicine Network; has three patents and a fourth patent pending; received travel/accommodations/meeting expenses unrelated to activities listed from American Institute of Ultrasound in Medicine, ASRM, and Femsys. Other relationships: is licensed from Wayne State to exclusively use high-throughput stem cell assays for embryo toxicity testing. **R.S.B.** disclosed no relevant relationships. **D.L.B.** disclosed no relevant relationships.

## References

- Levine D, Brown DL, Andreotti RF, et al. Management of asymptomatic ovarian and other adnexal cysts imaged at US: Society of Radiologists in Ultrasound Consensus Conference Statement. *Radiology* 2010;256(3):943–954.
- American College of Radiology for the Choosing Wisely campaign. Don't recommend follow-up imaging for clinically inconsequential adnexal cysts. 2012 [updated 6/29/2017; cited 2019 March 5]; Available from: <http://www.choosingwisely.org/clinician-lists/american-college-radiology-follow-up-imaging-for-adnexal-cysts/>.
- Ghosh E, Levine D. Recommendations for adnexal cysts: have the Society of Radiologists in Ultrasound consensus conference guidelines affected utilization of ultrasound? *Ultrasound Q* 2013;29(1):21–24.
- Maturen KE, Blaty AD, Wasnik AP, et al. Risk Stratification of Adnexal Cysts and Cystic Masses: Clinical Performance of Society of Radiologists in Ultrasound Guidelines. *Radiology* 2017;285(2):650–659.
- Smith-Bindman R, Ponder L, Johnson E, Miglioretti DL. Risk of Malignant Ovarian Cancer Based on Ultrasonography Findings in a Large Unselected Population. *JAMA Intern Med* 2019;179(1):71–77.
- Greenlee RT, Kessel B, Williams CR, et al. Prevalence, incidence, and natural history of simple ovarian cysts among women >55 years old in a large cancer screening trial. *Am J Obstet Gynecol* 2010;202(4):373.e1–373.e9.
- Sharma A, Gentry-Maharaj A, Burnell M, et al. Assessing the malignant potential of ovarian inclusion cysts in postmenopausal women within the UK Collaborative Trial of Ovarian Cancer Screening (UKCTOCS): a prospective cohort study. *BJOG* 2012;119(2):207–219.
- Savelli L, Ghi T, De Iaco P, Ceccaroni M, Venturoli S, Cacciatore B. Paraovarian/paratubal cysts: comparison of transvaginal sonographic and pathological findings to establish diagnostic criteria. *Ultrasound Obstet Gynecol* 2006;28(3):330–334.
- Sokalska A, Timmerman D, Testa AC, et al. Diagnostic accuracy of transvaginal ultrasound examination for assigning a specific diagnosis to adnexal masses. *Ultrasound Obstet Gynecol* 2009;34(4):462–470.
- Schallert EK, Abbas PI, Mehollin-Ray AR, Price MC, Dietrich JE, Orth RC. Physiologic Ovarian Cysts versus Other Ovarian and Adnexal Pathologic Changes in the Preadolescent and Adolescent Population: US and Surgical Follow-up. *Radiology* 2019;292(1):172–178.
- Levine D, Gosink BB, Wolf SI, Feldesman MR, Pretorius DH. Simple adnexal cysts: the natural history in postmenopausal women. *Radiology* 1992;184(3):653–659.
- Mesurrolle B, Helou T, El-Khoury M, Edwardes M, Sutton EJ, Kao E. Tissue harmonic imaging, frequency compound imaging, and conventional imaging: use and benefit in breast sonography. *J Ultrasound Med* 2007;26(8):1041–1051.
- Valentin L, Akrawi D. The natural history of adnexal cysts incidentally detected at transvaginal ultrasound examination in postmenopausal women. *Ultrasound Obstet Gynecol* 2002;20(2):174–180.
- Valentin L, Skoog L, Epstein E. Frequency and type of adnexal lesions in autopsy material from postmenopausal women: ultrasound study with histological correlation. *Ultrasound Obstet Gynecol* 2003;22(3):284–289.
- Suh-Burgmann E, Flanagan T, Osinski T, Alavi M, Herrinton L. Prospective Validation of a Standardized Ultrasonography-Based Ovarian Cancer Risk Assessment System. *Obstet Gynecol* 2018;132(5):1101–1111.
- Erickson BK, Conner MG, Landen CN Jr. The role of the fallopian tube in the origin of ovarian cancer. *Am J Obstet Gynecol* 2013;209(5):409–414.
- Obwegeser R, Deutinger J, Bernaschek G. The risk of malignancy with an apparently simple adnexal cyst on ultrasound. *Arch Gynecol Obstet* 1993;253(3):117–120.
- Hall DA, McCarthy KA. The significance of the postmenopausal simple adnexal cyst. *J Ultrasound Med* 1986;5(9):503–505.
- Menon U, Talaat A, Rosenthal AN, et al. Performance of ultrasound as a second line test to serum CA125 in ovarian cancer screening. *BJOG* 2000;107(2):165–169.
- Luxman D, Bergman A, Sagi J, David MP. The postmenopausal adnexal mass: correlation between ultrasonic and pathologic findings. *Obstet Gynecol* 1991;77(5):726–728.
- Goldstein SR, Subramanyam B, Snyder JR, Beller U, Raghavendra BN, Beckman EM. The postmenopausal cystic adnexal mass: the potential role of ultrasound in conservative management. *Obstet Gynecol* 1989;73(1):8–10.
- Herrmann UJ Jr, Locher GW, Goldhirsch A. Sonographic patterns of ovarian tumors: prediction of malignancy. *Obstet Gynecol* 1987;69(5):777–781.
- Andolf E, Jørgensen C. Simple adnexal cysts diagnosed by ultrasound in postmenopausal women. *J Clin Ultrasound* 1988;16(5):301–303.
- Luján Irazorza JE, Hernández Marín I, Figueroa Preciado G, Ayala AR. Prevalence of postmenopausal simple ovarian cyst diagnosed by ultrasound [in Spanish]. *Ginecol Obstet Mex* 2006;74(10):532–536.
- Kroon E, Andolf E. Diagnosis and follow-up of simple ovarian cysts detected by ultrasound in postmenopausal women. *Obstet Gynecol* 1995;85(2):211–214.
- Bayoğlu Tekin Y, Dede FS. What is the success of ultrasonography of benign adnexal masses? *J Obstet Gynaecol Res* 2014;40(2):473–478.
- Simcock B, Anderson N. Diagnosis and management of simple ovarian cysts: an audit. *Australas Radiol* 2005;49(1):27–31.
- Vuento MH, Pirhonen JP, Mäkinen JI, Laippala PJ, Grönroos M, Salmi TA. Evaluation of ovarian findings in asymptomatic postmenopausal women with color Doppler ultrasound. *Cancer* 1995;76(7):1214–1218.
- Conway C, Zalud I, Dilena M, et al. Simple cyst in the postmenopausal patient: detection and management. *J Ultrasound Med* 1998;17(6):369–372; quiz 373–374.
- Valentin L, Ameye L, Franchi D, et al. Risk of malignancy in unilocular cysts: a study of 1148 adnexal masses classified as unilocular cysts at transvaginal ultrasound and review of the literature. *Ultrasound Obstet Gynecol* 2013;41(1):80–89.
- Auslender R, Atlas I, Lissak A, Bornstein J, Atad J, Abramovici H. Follow-up of small, postmenopausal ovarian cysts using vaginal ultrasound and CA-125 antigen. *J Clin Ultrasound* 1996;24(4):175–178.
- McDonald JM, Doran S, DeSimone CP, et al. Predicting risk of malignancy in adnexal masses. *Obstet Gynecol* 2010;115(4):687–694.
- Hata K, Akiba S, Hata T, Miyazaki K. A multivariate logistic regression analysis in predicting malignancy for patients with ovarian tumors. *Gynecol Oncol* 1998;68(3):256–262.
- Jokubkiene L, Sladkevicius P, Valentin L. Does three-dimensional power Doppler ultrasound help in discrimination between benign and malignant ovarian masses? *Ultrasound Obstet Gynecol* 2007;29(2):215–225.
- Sasaki H, Oda M, Ohmura M, et al. Follow up of women with simple ovarian cysts detected by transvaginal sonography in the Tokyo metropolitan area. *Br J Obstet Gynaecol* 1999;106(5):415–420.
- Gramellini D, Fieni S, Sanapo L, Casilla G, Verrotti C, Nardelli GB. Diagnostic accuracy of IOTA ultrasound morphology in the hands of less experienced sonographers. *Aust N Z J Obstet Gynaecol* 2008;48(2):195–201.
- Timmerman D, Testa AC, Bourne T, et al. Logistic regression model to distinguish between the benign and malignant adnexal mass before surgery: a multicenter study by the International Ovarian Tumor Analysis Group. *J Clin Oncol* 2005;23(34):8794–8801.
- Bailey CL, Ueland FR, Land GL, et al. The malignant potential of small cystic ovarian tumors in women over 50 years of age. *Gynecol Oncol* 1998;69(1):3–7.
- Valentin L. Gray scale sonography, subjective evaluation of the color Doppler image and measurement of blood flow velocity for distinguishing benign and malignant tumors of suspected adnexal origin. *Eur J Obstet Gynecol Reprod Biol* 1997;72(1):63–72.
- Exacoustos C, Romanini ME, Rinaldo D, et al. Preoperative sonographic features of borderline ovarian tumors. *Ultrasound Obstet Gynecol* 2005;25(1):50–59.
- Modesitt SC, Pavlik EJ, Ueland FR, DePriest PD, Kryscio RJ, van Nagell JR Jr. Risk of malignancy in unilocular ovarian cystic tumors less than 10 centimeters in diameter. *Obstet Gynecol* 2003;102(3):594–599.
- Kurjak A, Shalan H, Kupesic S, et al. An attempt to screen asymptomatic women for ovarian and endometrial cancer with transvaginal color and pulsed Doppler sonography. *J Ultrasound Med* 1994;13(4):295–301.
- Elder JW, Pavlik EJ, Long A, et al. Serial ultrasonographic evaluation of ovarian abnormalities with a morphology index. *Gynecol Oncol* 2014;135(1):8–12.

44. Cohen I, Potlog-Nahari C, Shapira J, Yigael D, Tepper R. Simple ovarian cysts in postmenopausal patients with breast carcinoma treated with tamoxifen: long-term follow-up. *Radiology* 2003;227(3):844–848.
45. Osmer RG, Osmer M, von Maydell B, Wagner B, Kuhn W. Evaluation of ovarian tumors in postmenopausal women by transvaginal sonography. *Eur J Obstet Gynecol Reprod Biol* 1998;77(1):81–88.
46. Reimer T, Gerber B, Müller H, Jeschke U, Krause A, Friese K. Differential diagnosis of peri- and postmenopausal ovarian cysts. *Maturitas* 1999;31(2):123–132.
47. Myers E, Bastian L, Havrilesky L, et al. Management of Adnexal Mass. Evidence Report/Technology Assessment No.130 (Prepared by the Duke Evidence-based Practice Center under Contract No. 290-02-0025.). Agency for Healthcare Research and Quality. Rockville, MD2006.
48. Ekerhovd E, Wienerroith H, Staudach A, Granberg S. Preoperative assessment of unilocular adnexal cysts by transvaginal ultrasonography: a comparison between ultrasonographic morphologic imaging and histopathologic diagnosis. *Am J Obstet Gynecol* 2001;184(2):48–54.
49. Gerber B, Müller H, Külz T, Krause A, Reimer T. Simple ovarian cysts in premenopausal patients. *Int J Gynaecol Obstet* 1997;57(1):49–55.
50. Jain KA. Prospective evaluation of adnexal masses with endovaginal gray-scale and duplex and color Doppler US: correlation with pathologic findings. *Radiology* 1994;191(1):63–67.
51. Rodríguez MH, Platt LD, Medearis AL, Lacarra M, Lobo RA. The use of transvaginal sonography for evaluation of postmenopausal ovarian size and morphology. *Am J Obstet Gynecol* 1988;159(4):810–814.
52. Schoenfeld A, Levavi H, Hirsch M, Pardo J, Ovadia J. Transvaginal sonography in postmenopausal women. *J Clin Ultrasound* 1990;18(4):350–358.
53. Ueland FR, DePriest PD, Pavlik EJ, Kryscio RJ, van Nagell JR Jr. Preoperative differentiation of malignant from benign ovarian tumors: the efficacy of morphology indexing and Doppler flow sonography. *Gynecol Oncol* 2003;91(1):46–50.
54. Xiaoman D, Jinhua L, Jinghe L, Huajun L. Evaluation of surgery in simple ovarian cysts. *Chin Med Sci J* 2003;18(2):93–96.
55. Yamashita Y, Torashima M, Hatanaka Y, et al. Adnexal masses: accuracy of characterization with transvaginal US and precontrast and postcontrast MR imaging. *Radiology* 1995;194(2):557–565.
56. Parazzini F, Frattaruolo MP, Chiaffarino F, Dridi D, Roncella E, Vercellini P. The limited oncogenic potential of unilocular adnexal cysts: A systematic review and meta-analysis. *Eur J Obstet Gynecol Reprod Biol* 2018;225:101–109.
57. Allison KH, Swisher EM, Kerkering KM, Garcia RL. Defining an appropriate threshold for the diagnosis of serous borderline tumor of the ovary: when is a full staging procedure unnecessary? *Int J Gynecol Pathol* 2008;27(1):10–17.
58. Kurman R, Carcangui M, Herrington CS, RHE Y. WHO classification of the reproductive organs. Lyon: IARC, 2014.
59. Shalev E, Eliyahu S, Peleg D, Tsabari A. Laparoscopic management of adnexal cystic masses in postmenopausal women. *Obstet Gynecol* 1994;83(4):594–596.
60. Nunes N, Ambler G, Foo X, et al. Comparison of two protocols for the management of asymptomatic postmenopausal women with adnexal tumours: a randomised controlled trial of RMI/RCOG vs Simple Rules. *Br J Cancer* 2017;116(5):584–591.
61. Aubert JM, Rombaut C, Argacha P, Romero F, Leira J, Gomez-Bolea F. Simple adnexal cysts in postmenopausal women: conservative management. *Maturitas* 1998;30(1):51–54.
62. Alcázar JL, Castillo G, Jurado M, García GL. Is expectant management of sonographically benign adnexal cysts an option in selected asymptomatic premenopausal women? *Hum Reprod* 2005;20(11):3231–3234.
63. Nardo LG, Kroon ND, Reginald PW. Persistent unilocular ovarian cysts in a general population of postmenopausal women: is there a place for expectant management? *Obstet Gynecol* 2003;102(3):589–593.
64. Sarkar M, Wolf MG. Simple ovarian cysts in postmenopausal women: scope of conservative management. *Eur J Obstet Gynecol Reprod Biol* 2012;162(1):75–78.
65. Castillo G, Alcázar JL, Jurado M. Natural history of sonographically detected simple unilocular adnexal cysts in asymptomatic postmenopausal women. *Gynecol Oncol* 2004;92(3):965–969.
66. van Nagell JR Jr, Miller RW. Evaluation and Management of Ultrasonographically Detected Ovarian Tumors in Asymptomatic Women. *Obstet Gynecol* 2016;127(5):848–858.
67. Fallowfield L, Fleissig A, Barrett J, et al. Awareness of ovarian cancer risk factors, beliefs and attitudes towards screening: baseline survey of 21,715 women participating in the UK Collaborative Trial of Ovarian Cancer Screening. *Br J Cancer* 2010;103(4):454–461.
68. van Nagell JR Jr, Burgess BT, Miller RW, et al. Survival of Women With Type I and II Epithelial Ovarian Cancer Detected by Ultrasound Screening. *Obstet Gynecol* 2018;132(5):1091–1100.
69. US Preventive Services Task Force, Grossman DC, Curry SJ, et al. Screening for Ovarian Cancer: US Preventive Services Task Force Recommendation Statement. *JAMA* 2018;319(6):588–594.
70. Pinsky PF, Yu K, Kramer BS, et al. Extended mortality results for ovarian cancer screening in the PLCO trial with median 15 years follow-up. *Gynecol Oncol* 2016;143(2):270–275.
71. Jacobs IJ, Menon U, Ryan A, et al. Ovarian cancer screening and mortality in the UK Collaborative Trial of Ovarian Cancer Screening (UKCTOCS): a randomised controlled trial. *Lancet* 2016;387(10022):945–956.
72. Froyman W, Landolfo C, De Cock B, et al. Risk of complications in patients with conservatively managed ovarian tumours (IOTA5): a 2-year interim analysis of a multicentre, prospective, cohort study. *Lancet Oncol* 2019;20(3):448–458.
73. Baldwin LA, Pavlik EJ, Ueland E, et al. Complications from Surgeries Related to Ovarian Cancer Screening. *Diagnostics (Basel)* 2017;7(1):E16.
74. Levine D. Evaluating an Asymptomatic Adnexal Cyst Found on Pelvic Ultrasonography. *JAMA Intern Med* 2019;179(1):78–79.
75. Doubilet PM, Benson CB, Bourne T, et al. Diagnostic criteria for nonviable pregnancy early in the first trimester. *N Engl J Med* 2013;369(15):1443–1451.
76. Andreotti R. O-rads management. 2019: in press.
77. Suh-Burgmann E, Hung YY, Kinney W. Outcomes from ultrasound follow-up of small complex adnexal masses in women over 50. *Am J Obstet Gynecol* 2014;211(6):623.e1–623.e7.
78. Pavlik EJ, Ueland FR, Miller RW, et al. Frequency and disposition of ovarian abnormalities followed with serial transvaginal ultrasonography. *Obstet Gynecol* 2013;122(2 Pt 1):210–217.
79. van Nagell JR Jr, DePriest PD, Ueland FR, et al. Ovarian cancer screening with annual transvaginal sonography: findings of 25,000 women screened. *Cancer* 2007;109(9):1887–1896.
80. UpToDate. Evidence Grading Guide. <https://www.uptodate.com/home/grading-guide#FactorsStrongWeak>. 2019.
81. American College of Obstetricians and Gynecologists' Committee on Practice Bulletins—Gynecology. Practice Bulletin No. 174: Evaluation and Management of Adnexal Masses. *Obstet Gynecol* 2016;128(5):e210–e226.
82. Glanc P, Benacerraf B, Bourne T, et al. First International Consensus Report on Adnexal Masses: Management Recommendations. *J Ultrasound Med* 2017;36(5):849–863.
83. Patel MD, Ascher SM, Paspulati RM, et al. Managing incidental findings on abdominal and pelvic CT and MRI, part 1: white paper of the ACR Incidental Findings Committee II on adnexal findings. *J Am Coll Radiol* 2013;10(9):675–681.
84. de Kroon CD, van der Sandt HA, van Houwelingen JC, Jansen FW. Sonographic assessment of non-malignant ovarian cysts: does sonohistology exist? *Hum Reprod* 2004;19(9):2138–2143.